

labline

DENTAVANTGART

VOLUME VI ISSUE 03 AUTUMN 2016

INTERVIEW

DR. **SIDNEY KINA**

DENTAL KNOWLEDGE
AND ZEN

DT. **SÉBASTIEN MOSCONI** &
DR. **MARIE CLÉMENT** &
DR. **CYRIL GAILLARD** &
DR. **RENAUD NOHARET**

**DETAILED,
ILLUSTRATED
REVIEW OF THE
LIVE PATIENT
COURSE**

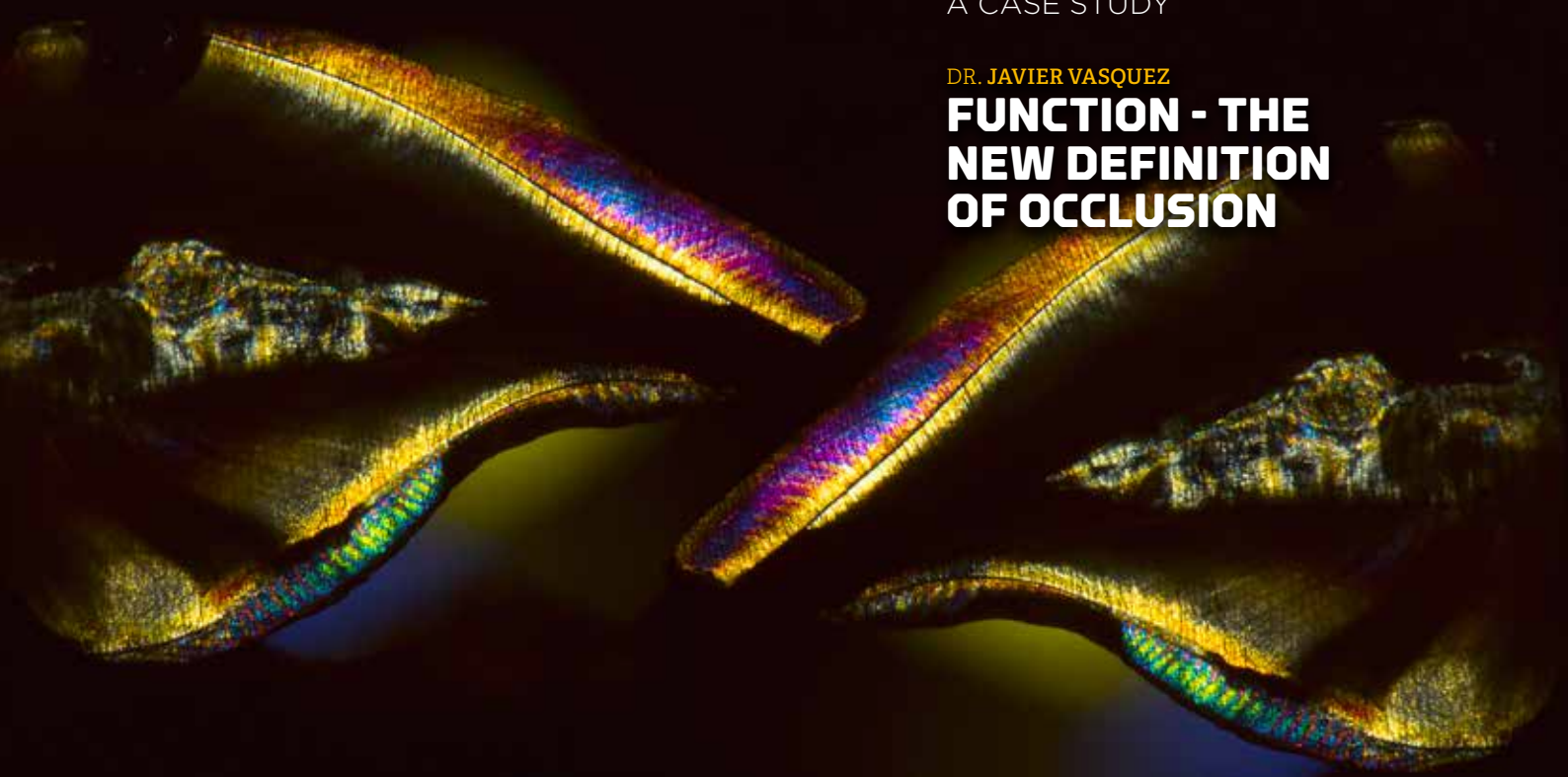MDT. **NONDAS VLACHOPOULOS** &
DR. **DIMITRIOS SPAGOPOULOS** &
DR. **EFSTRATIOS PAPAZOGLU**

**AESTHETIC
REHABILITATION
USING
FELDSPATHIC
VENEERS**

A CASE STUDY

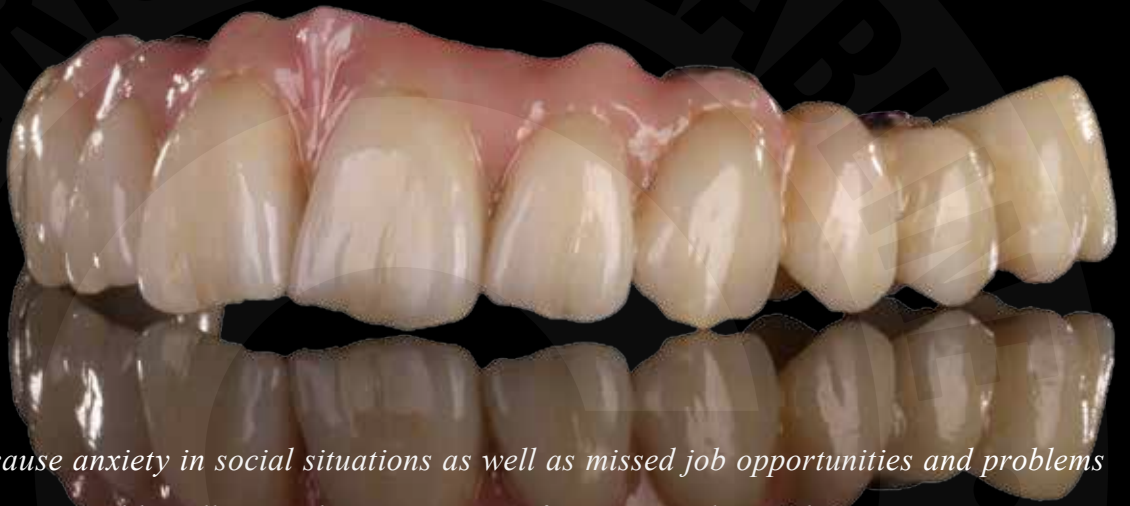DR. **JAVIER VASQUEZ**

**FUNCTION - THE
NEW DEFINITION
OF OCCLUSION**

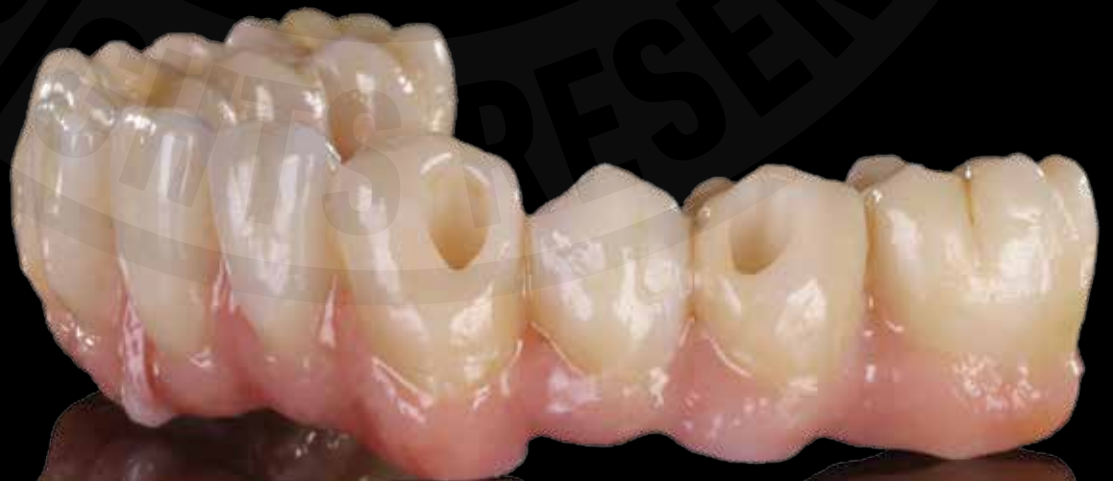

COMPLETE MAXILLARY AND MANDIBULAR REHABILITATION

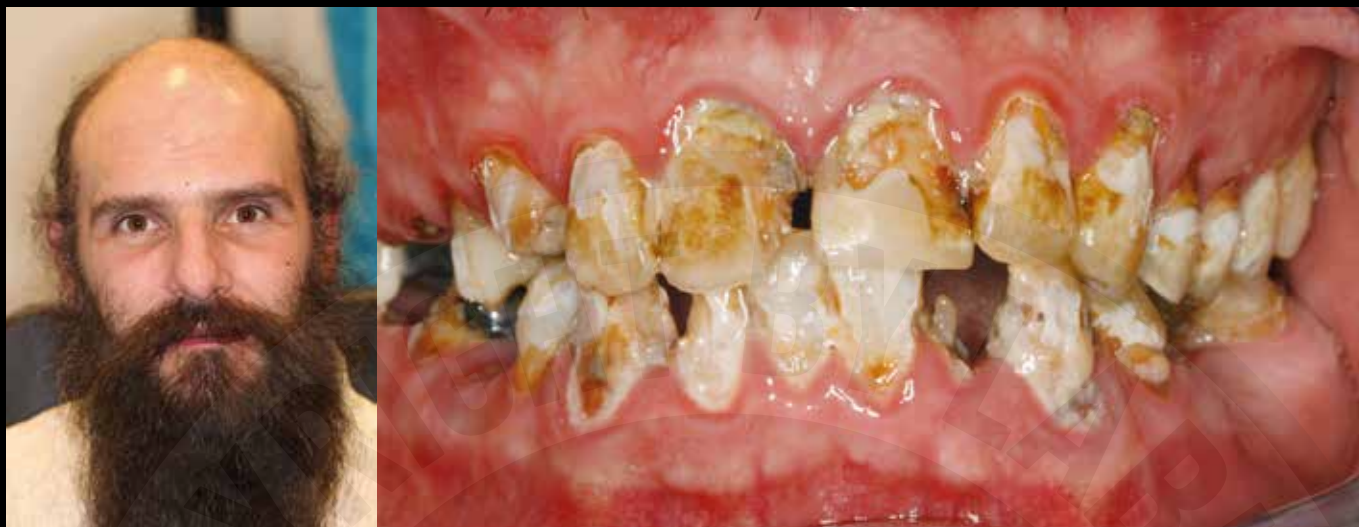USING PRETTAU® ZIRCONIA



Missing teeth can cause anxiety in social situations as well as missed job opportunities and problems in basic everyday activities like talking and eating. Cases of patients with social anxiety can present a challenge for us (dental technicians) and dentists, aware of the important role that an accurate dental service can play in improving the social situation of the affected patient. A heightened sense of trust facilitates the interactions between the patient, his dentist and the dental technician. The case herein described shows how CAD/CAM technology and the digital workflow can help dentists and technicians to provide a highly precise and aesthetically satisfactory result for their patients.



BASELINE SITUATION



*1a, 1b
 Clinical baseline situation of the patient*

A 43-year-old, male patient presented to his dentist Bjørn Gunnar Benjaminsen at Melhus Tannhelse, Melhus, with severe carious lesions in all teeth, and multiple radix relicta (Figs. 1a, 1b and 2). According to the dentist, the patient

“had not been to a dentist for almost 15 years. The challenge was to treat the patient who has a strong fear of dentists and dental treatments. [...] He was suffering from social anxiety, as he did not have teeth. He was working nights and stayed at home during the day. [...] I discovered that he had suffered from dental treatment anxiety for many years, but was unable to produce any documentation regarding anxiety from his dentist, as he barely saw any dentists.”

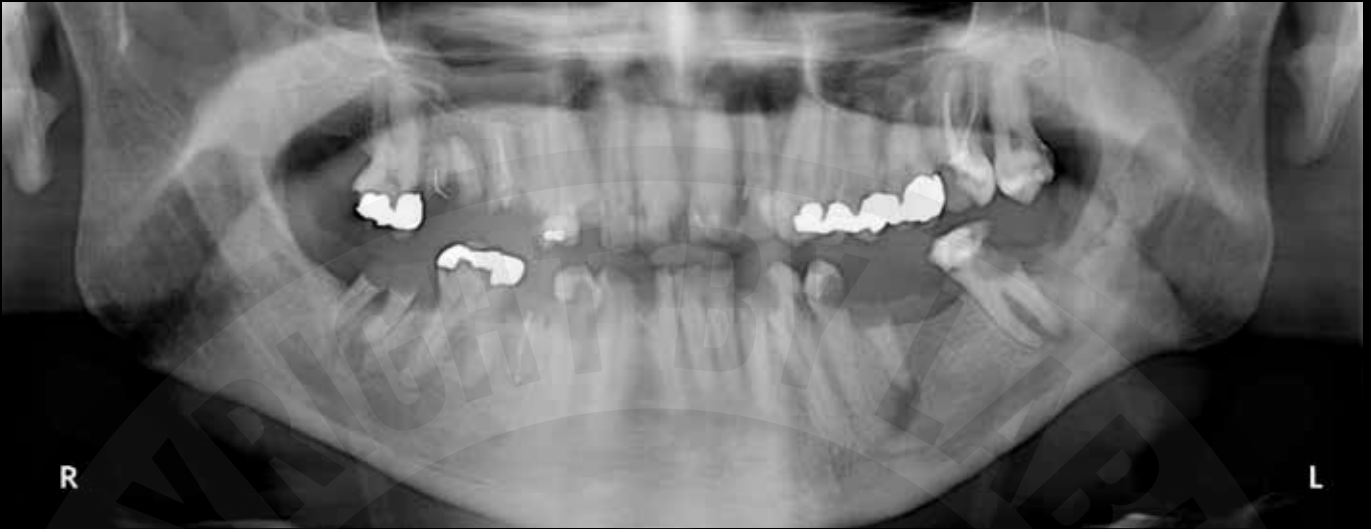
Too much pain in his teeth was the reason to encourage him to overcome his anxiety and seek consultation. His primary wish was to take out all of his teeth and have implants: the pain was so strong that he could not brush his teeth and, during the winter, he had to eat snow for relief.

“I had to start the treatment as the situation strongly affected the patient sociologically. [...] It was no longer possible to save the patient’s teeth, also he definitely did not want to keep them. He did not want to have dentures, as he was not willing to use something removable. He wished, however, to put fixtures in rather quickly.”

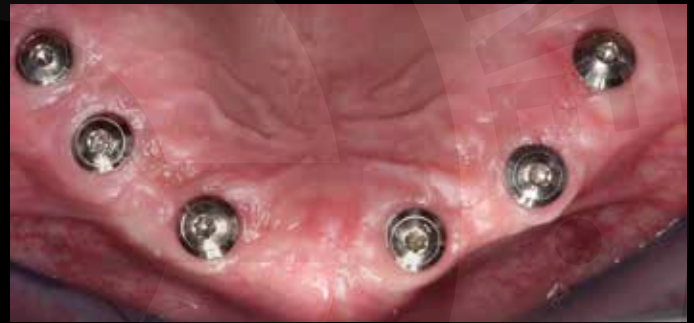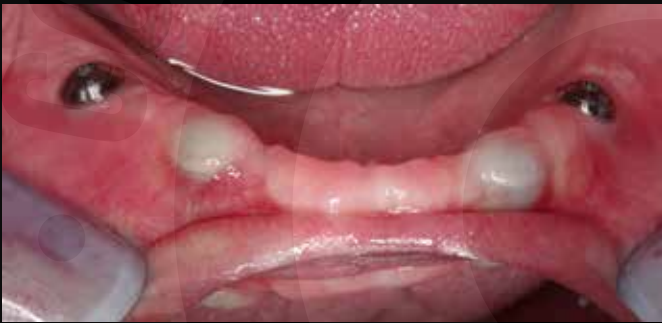The patient required a fixed, painless, lasting and secure solution that could allow him to carry out normal basic activities like eating and cleaning. The dentist, on the other hand, wanted the patient to wear a restoration that would be easy to maintain, and that would not compel the patient to perform constant dental controls. Several removable solutions could have been possibly used to treat this case, like complete overdentures, screw retained bridges, or overdenture combinations (bridgework with Bego clips and overdentures on 2 ball clip attachments). However, a complete maxillary and mandibular rehabilitation in Prettau® Zirconia on implants was the best solution for this case, because a fixed rehabilitation was the only kind of prosthesis accepted by the patient. Zirkozahn’s Prettau® Zirconia was chosen for the material because of its long-lasting durability and because of its plaque resistant properties, allowing the patient to maintain his oral hygiene without the need of chair-side cleaning.



REALISATION OF THE MAXILLARY AND MANDIBULAR REHABILITATION IN PRETTAU, SLOVACIA



2
Radiography of the patient's baseline situation



3, 4
Implants in the upper and lower jaws

In the first treatment phase, the dentist placed the implants at sites 12-22-14-16-24-26 and 32-42-35-45. As a result of the surgical phase, 10 implants were now present in the patient's mouth: 6 in the upper jaw and 4 in the lower jaw (Figs. 3 and 4). An impression of the situation was then taken and sent to us (Art in Dent dental laboratory in collaboration with Zirkonzahn).

Our first step was to acquire the digital data of the patient's situation. The master model, with implant analogues, was mounted in the articulator and scanned using Zirkonzahn's S600 ARTI scanner (Fig. 5). In order to detect the implant positions in regards to the model and select appropriate titanium bases, we used titanium Scanmarkers (Fig. 6).



5
S600 ARTI scanner with articulator (Zirkonzahn)



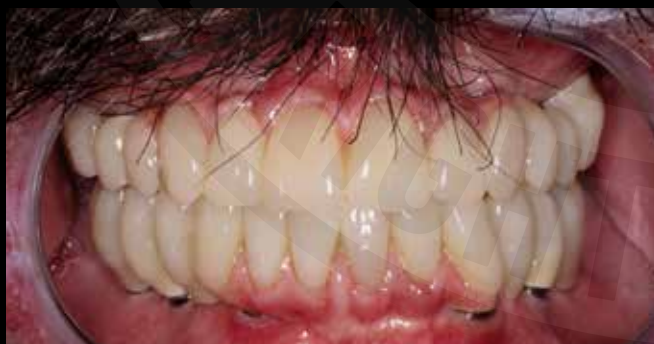6
Example of master cast with Scanmarkes (Zirkonzahn)



7
 Recording of the patient's NHP and facial data through Zirkozahn's PlaneSystem® and the Face Hunter

At this stage of the workflow, the new devices developed in dental technology can significantly help dental technicians obtain much more precise data for a highly accurate final rehabilitation. For the purpose of this restoration, we used the Face Hunter facial scanner and the PlaneSystem®, developed by MDT Udo Plaster in collaboration with Zirkozahn. The Face Hunter and PlaneSystem® allow the user to acquire the Natural Head Position (NHP) of the patient as well as his facial data, and to record the patient's face in three dimensions (Fig. 7). The obtained data will be implemented into the Zirkozahn.Modellier software coordination system for the digital modeling of the rehabilitation.

The combination of the acquired data with digital modeling allows the user to customise the restoration for the patient in terms of both jaw relations and aesthetics. Our next step was to choose the anatomic tooth morphology that could best fit the patient's physiognomy. From the Zirkozahn's "Heroes Collection" virtual tooth library, we selected the Seraphim tooth morphology for both jaws, and we aligned it in relation to the diagnostic cast in order to preview how it could suit the patient's facial physiognomy. Only minor changes were applied: the upper and lower jaws of each set of the "Heroes Collection" are in fact naturally fitting in terms of occlusion and the virtual articulator automatically adjusts any occlusal interference through a mandibular function simulator.



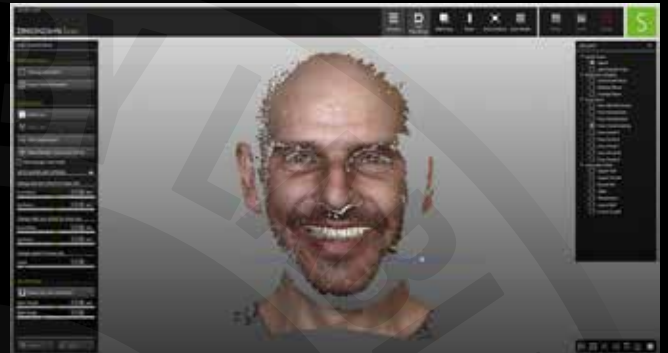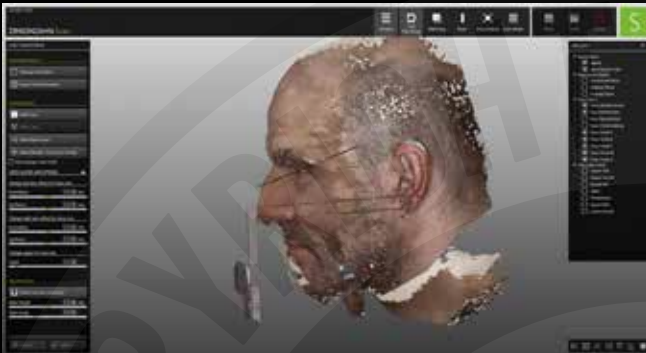8
 The prototype milled in Temp Premium resin with Gingiva-Composites (Zirkozahn)

Based on the acquired digital data, a resin prototype was then produced for the initial intraoral try-in, to let the dentist and the patient have a realistic preview of the final restoration in terms of occlusion, phonetics and aesthetics (Fig. 8). The prototype was milled in Temp Premium resin and veneered with Gingiva-Composites, but the new Multistratum® Flexible, a five-colour shading resin that reproduces the natural colours of the teeth from the dentine to the enamel, can now be chosen for an even more natural and aesthetic result.



The prototype met both the patient's and the dentist's requirements, therefore, we did not apply any changes. The patient kept the prototype in his mouth for two months. During this period, we could notice the importance that even the prototype had in our patient's social and everyday life: he shaved his beard and he started feeling more and more at ease in performing everyday normal activities.

After these two months, we checked the prototype, which disclosed the actual occlusion of the patient. The prototype appeared to be good in terms of aesthetics, phonetics and occlusion. However, since the beard could sometimes lead to imperfect results in the creation of a prosthesis, we decided to carry out a further test and make another prototype before milling the final restoration in zirconia. We scanned the patient's prototype and acquired his facial data a second time wearing the temporary restoration, by means of the PlaneSystem® and Face Hunter. We implemented the data into the software (Figs. 9a and 9b) and applied a few minor changes.



9a and 9b
The digitisation of the patient's face with the prototype

Thanks to CAD/CAM technology, in a very short time a new prototype was milled in Temp Basic resin. At this stage, in order to perform a more comprehensive and precise check of the new prototype, we combined virtual and physical checks of his situation. This was possible by means of Zirkozahn's physical articulator PSI, PlanePositioner® and JawPositioner, which provide an exact physical reproduction of the digital data. First of all, via the new M4 Wet Heavy Metal Milling Unit, we milled the patient situation in the JawPositioner. This was then mounted on the PlanePositioner®, which allows adjusting the patient's identified planes in order to recreate his exact situation in the physical world. This means that we have reference points both in the physical and in the virtual worlds. Thanks to these technologies, we could combine digital and manual working steps in order to get the advantages of both methods and obtain an excellent result in terms of accuracy (Figs. 10a, 10b and 10c). After the final checks, we used the new prototype as a wax-up for modelling the final restoration.



10a, 10b, 10c
The virtual articulator, the JawPositioner and the physical articulator PSI (Zirkozahn)



We milled the final structure in Prettau® Zirconia using the M4 Wet Heavy Metal Milling Unit (Fig. 11).

During the sintering process, connectors and a sintering stabiliser were used to prevent any distortion of the material and obtain a much more precise result (Figs. 12 and 13).

Full-arch bridge restorations must be sufficiently stabilised in order to avoid framework distortion during the sintering process in the furnace.

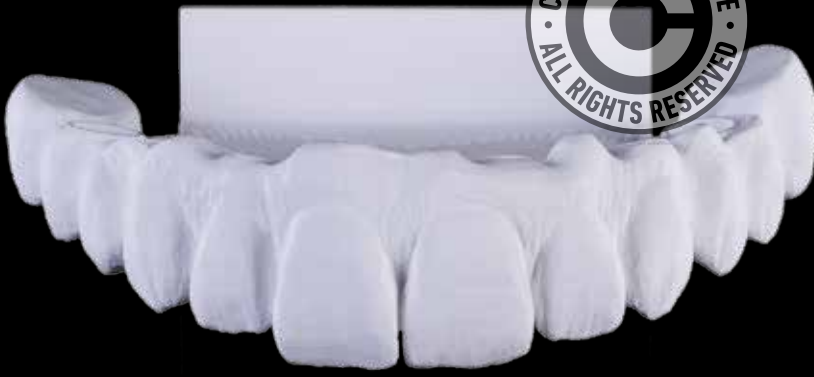A sintering support in the form of a so-called sintering foot should be provided for all bridges of three units or more. One legal point to observe is that dimensionally accurate sintering of dental ceramics using a sintering foot is protected by a patent granted to 3M (EP 1154969 B2) and therefore requires the user of the technology to obtain a licence. Zirkozahn has secured this licence for its dental materials on behalf of its customers until the end of the patent term. Information on whether a valid license is available can be obtained from the manufacturer of the respective zirconia material or from the patent owner.



11
M4 Wet Heavy Metal Milling Unit (Zirkozahn)



12, 13
The milled structure with connectors and sintering stabiliser




14, 15
The upper structure before and after the cut-back reduction



16, 17
The upper structure coloured with Colour Liquid Prettau® Aquarell (Zirkonzahn)

Once separated from the material blank, a manual cut-back reduction was performed on the Prettau® Zirconia restoration (Figs. 14 and 15). As an alternative to manual reduction, it is possible to reduce the tooth's shape digitally or to choose an already reduced tooth design directly from Zirkonzahn's tooth library.

The teeth were then coloured with Colour Liquid Prettau® Aquarell, water-based and acid-free liquids with special bio-pigments which give a realistic shade distribution and colour grading to the teeth (Figs. 16 and 17) and sintered overnight under vacuum in the Zirkonofen 700 Ultra-Vakuum furnace, suitable for both zirconia and sinter metal (Fig. 18).



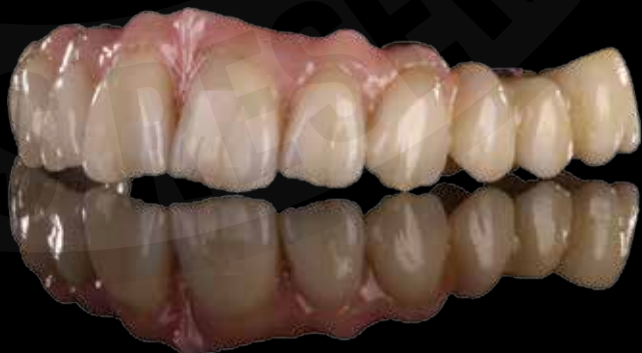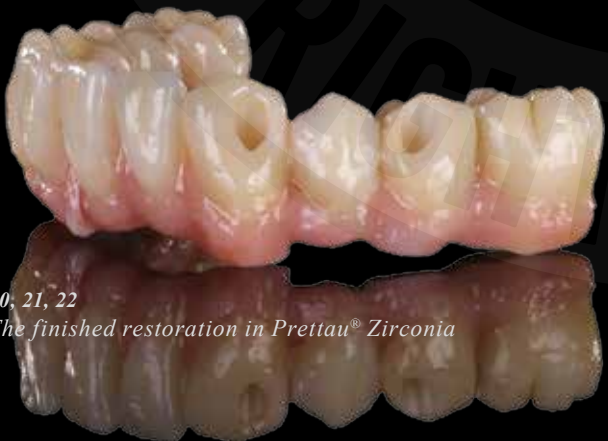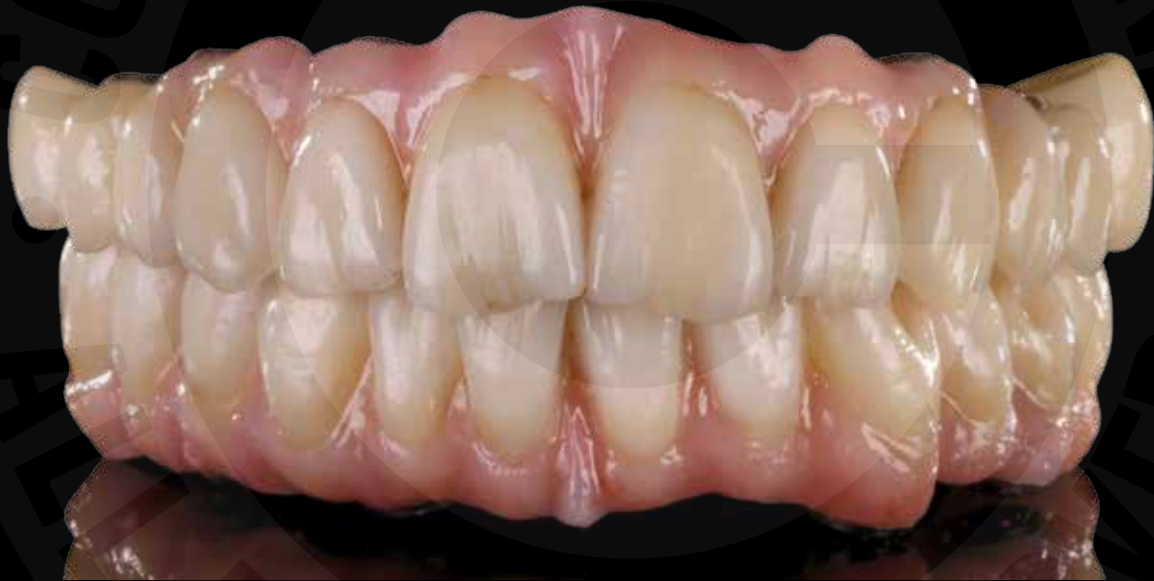18
Zirkonofen 700 Ultra-Vakuum (Zirkonzahn)



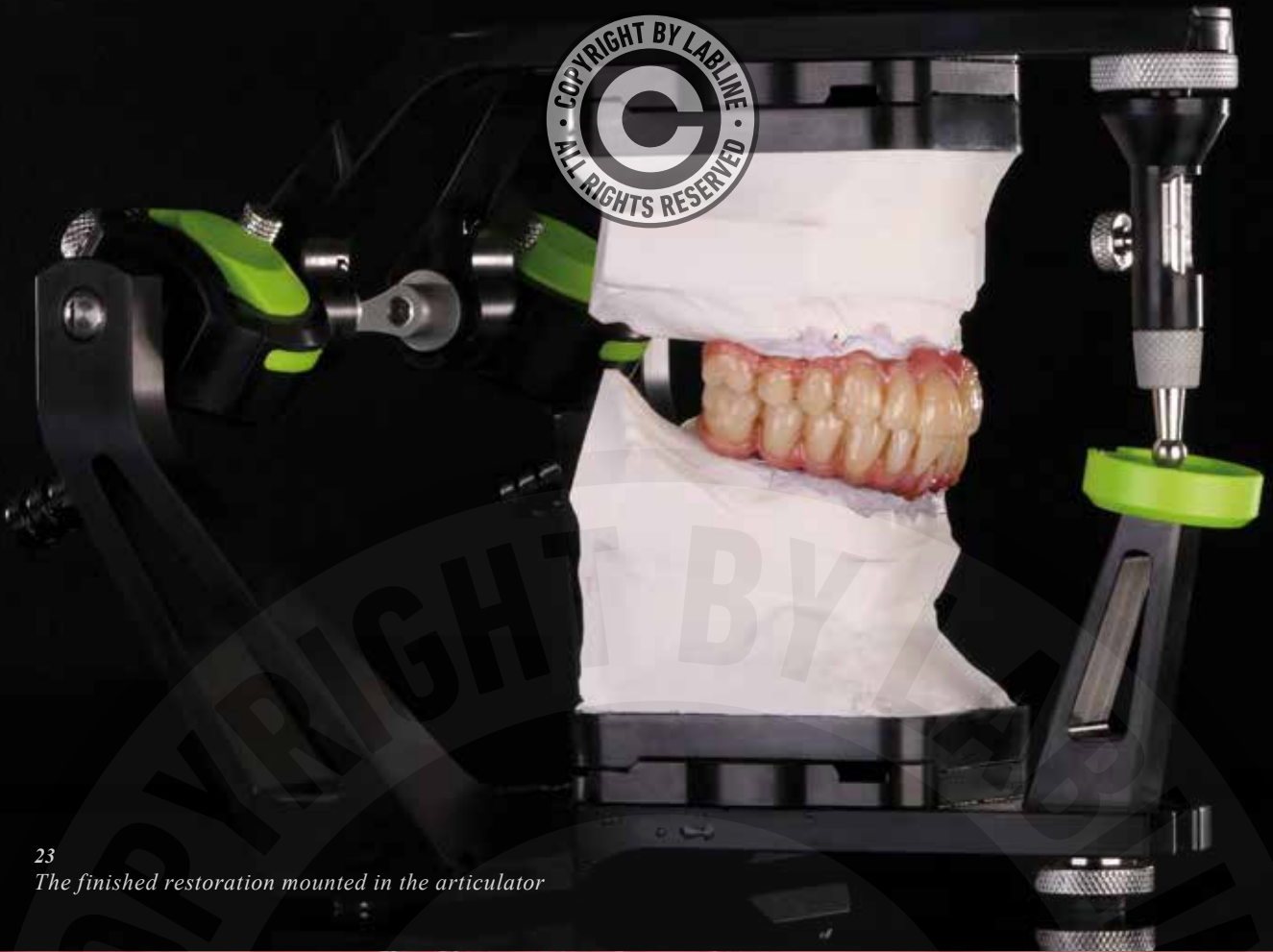After the removal of the connectors and the stabiliser, the restorations were layered using different kinds of ICE Zirkon Ceramics on the gingival area and on the vestibular sides of the anterior teeth (Enamel, Transpa and different colours for the gingiva tissue), starting with the wash, then dentine firing, followed by the final enamel and translucent effects. The restoration was then stained with ICE Zirkon 3D Stains by Enrico Steger and glazed. Once the final firing with stains and glaze was completed, the two structures were bonded to the titanium bases, which had been anodised to a gingival colour (Fig. 19) using the Titanium spectral-colouring Anodizer (Zirkonzahn, Italy), for better concealment under the zirconia structure. The finished restoration (Figs. 20, 21 and 22) completed with the titanium bases was then screwed into the master model to check its fit in the articulator (Fig. 23) and finally screwed into the patient's mouth (Figs. 24 and 25).



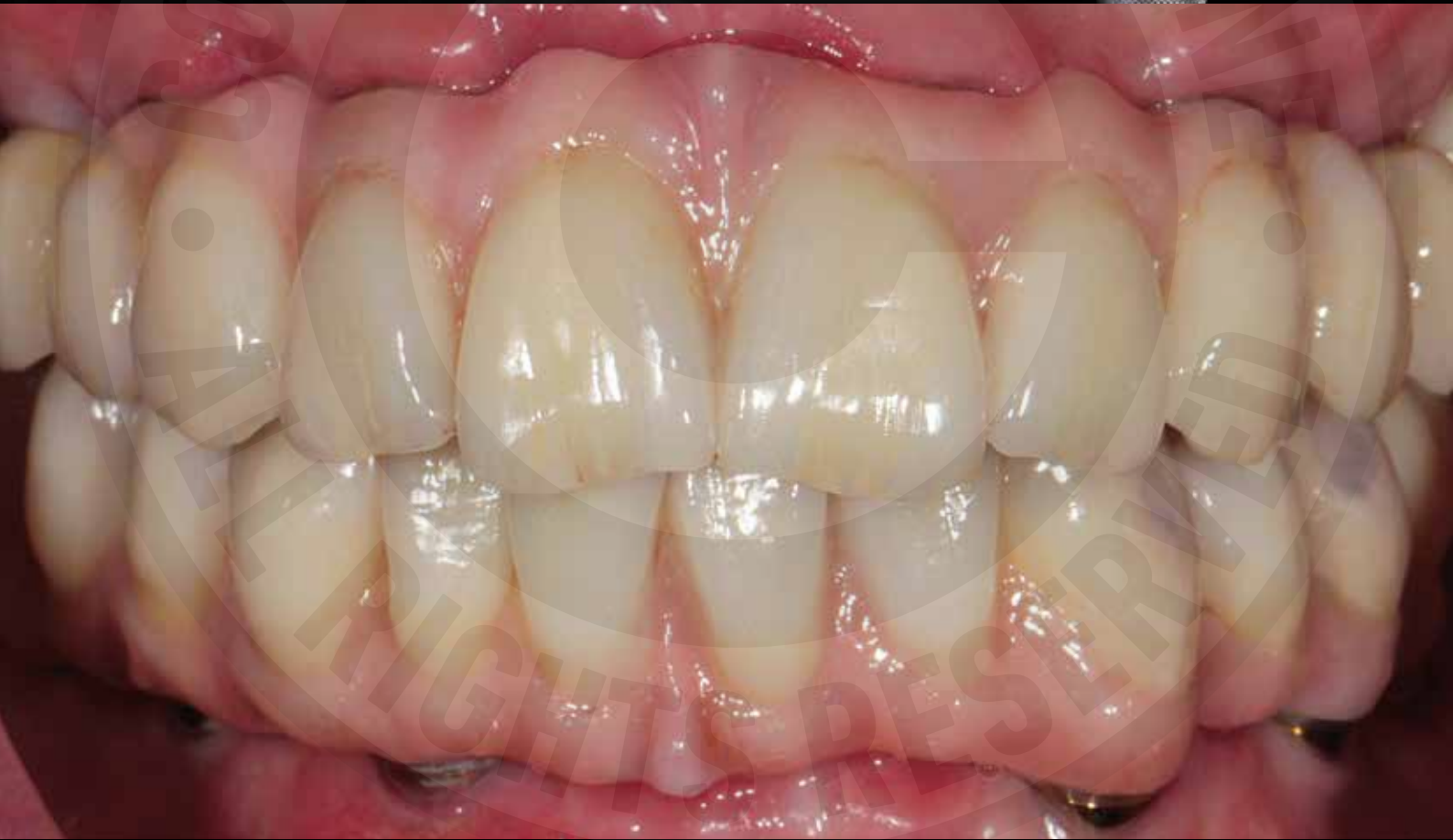19
Titanium bases anodised to a gingival colour (Zirkonzahn)




20, 21, 22
The finished restoration in Prettau® Zirconia



23
The finished restoration mounted in the articulator



24, 25
The final restoration screwed in the patient's mouth



CONCLUSION



We all agreed that the rehabilitation here described was very challenging and at the same time satisfactory. According to the dentist,

“It was good to observe how much one can help both sociologically and socially in creating such a rehabilitation. The patient shaved off his beard, which he used to hide behind for some years.”

This case gave us proof that dentists' and technicians' own abilities in combination with the precision obtained by the new digital workflow makes it possible to provide an accurate and aesthetically suitable rehabilitation, with the full satisfaction of the patient.

CASE REALISATION

Dr. Bjørn Gunnar Benjaminsen – Melhus Tannhelse, Melhus, Norway

MDT Bjørn Borten – Art in Dent, Trondheim, Norway

DT Stein Aanerud – Art in Dent, Kongsvinger, Norway

DT Julianna Janovics – Art in Dent, Trondheim, Norway

DT Bence Szabo – Art in Dent, Trondheim, Norway

In collaboration with:

MDT Antonio Corradini – Zirkonzahn Education Center Brunico, Italy